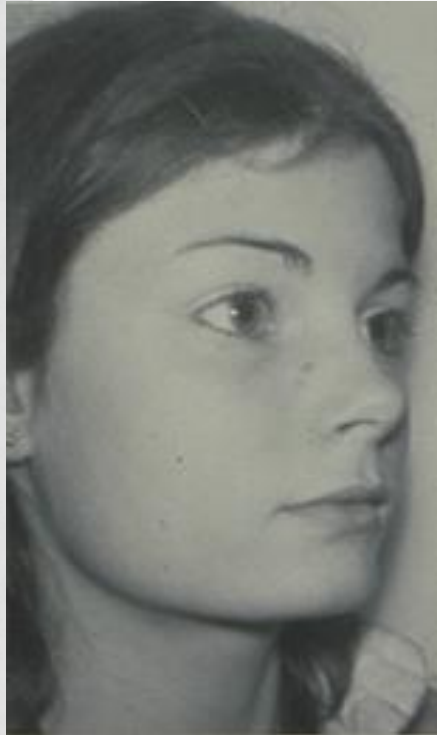

# ORTHOTROPICS

Dr John Mew

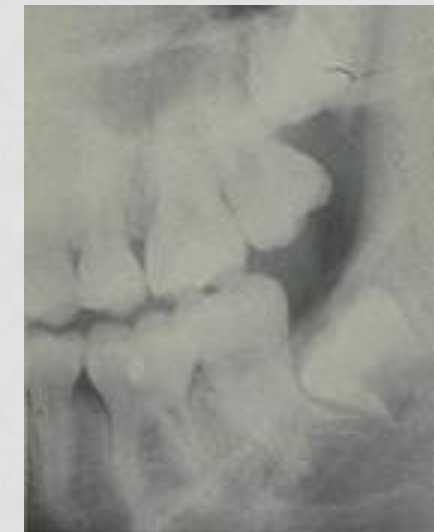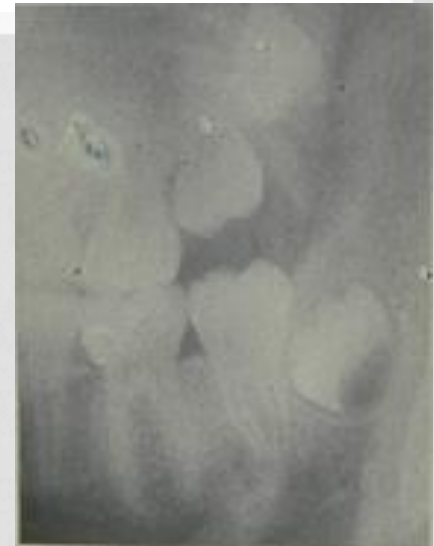


**Age 13**



**Age 15**

**Victoria.** Note how the ascending ramus has moved back from the lower second molar leaving room for the wisdom.



Note also the change in molar relationship

